Hernia (2024) 28:53–61
https://doi.org/10.1007/s10029-023-02848-2

ORIGINAL ARTICLE

Volumetry after botulinum toxin A: the impact on abdominal wall compliance and endotracheal pressure

P. H. F. Amaral[1,2] · J. Z. Macret[1,2] · E. R. M. Dias[1,2] · J. P. V. Carvalho[1,2] · L. G. A. Pivetta[1,2] · H. B. Ribeiro[1] · M. Y. Franciss[1] · R. A. Silva[1] · C. A. Malheiros[1] · S. Roll[1,2]

Received: 23 March 2023 / Accepted: 23 July 2023 / Published online: 10 August 2023
© The Author(s), under exclusive licence to Springer-Verlag France SAS, part of Springer Nature 2023

Abstract

Purpose Botulinum toxin type A (BTA) is an adjuvant tool used in the preoperative optimization of complex hernias before abdominal wall reconstruction (AWR). This study aims to investigate changes in the abdominal cavity and hernia sac dimensions after BTA application.

Method A prospective study with 27 patients with a hernia defect of ≥ 10 cm and loss of domain (LOD) ≥ 20% underwent AWR. Computed tomography (CT) measurements and volumetry before and after the application of BTA were performed. Intraoperative and postoperative outcomes were evaluated.

Results Imaging post-BTA revealed hernia width reduction of 1.9 cm ($p = 0.002$), lateral abdominal wall muscle elongation of 3.1 cm ($p < 0.001$), hernia volume reduction (HV) from 2.9 ± 0.9L to 2.4 ± 0.8L ($p < 0.001$), increase in abdominal cavity volume (ACV) from 9.7 ± 2.5L to 10.3L ± 2.4L ($p = 0.003$), and a reduction in the HV/ACV ratio from 30.2 ± 5% to 23.4 ± 6% ($p < 0.001$). Fascial closure was achieved in 92.6% of cases and component separation was required in 78%. The average variation in pulmonary plateau pressure was 3.53 cmH_2O, and there were no postoperative respiratory failure recorded. At the 90-day follow-up, the wound morbidity rate was 25%, unplanned readmissions were 11%, and hernia recurrence 7.4%.

Conclusion BTA produces measurable volumetric changes in abdominal wall and appears to facilitate fascial closure. Further studies are required to determine the role of BTA in the surgical armamentarium for complex hernia repair.

Keywords Complex ventral hernia · Botulinum toxin A · Abdominal wall reconstruction · Chemical component paralysis · Preoperative management · Background

Background

Ventral hernia repair is a common procedure practiced by a wide variety of surgeons [1, 2] accounting for 600,000 procedures per year in the USA with an estimated annual cost of $9.7 billion [3]. Historically, it has been linked to high rates of complications, unplanned readmissions and hernia recurrence [4, 5]. Large incisional hernias in the setting of associated comorbidities, wound contamination and loss of domain (LOD) are difficult to manage and often require abdominal wall reconstruction (AWR) [6].

Midline fascial closure during surgical repair is deemed crucial to restore abdominal wall function. Inability to close fascia results in need for bridging mesh rand has been associated with increased risk of recurrence, surgical site occurrences and worse quality of life [7, 8]. Nevertheless, oftentimes fascial closure can only be achieved under non-physiologic tension despite the use of myofascial releases and can result in postoperative intraperitoneal hypertension and respiratory failure [9, 10].

From preoperative CT scan, it is possible to predict whether component separation [11] will be necessary, calculate the ratio between hernia volume (HV) and abdominal cavity volume (ACV) [12] or even predict the need for intensive care [13], all of which are important for surgical planning. In cases where component separation is predicted, an adjunct method is used for abdominal cavity expansion such

✉ P. H. F. Amaral
pedro.amaral@fcmsantacasasp.edu.br

1 Santa Casa de Sao Paulo - Abdominal Wall Surgery Unit, Rua Cesário Mota Júnior, 112 - Vila Buarque, São Paulo, SP, Brazil

2 Hospital Alemão Oswaldo Cruz, Hernia Center, São Paulo, SP, Brazil

as progressive pneumoperitoneum or more recently chemical component separation by means of injection of botulinum toxin type A (BTA) [14]. This neurotoxin acts selectively on presynaptic cholinergic nerve terminals by blocking acetylcholine release, which promotes paralysis, flaccidity and elongation of the fibers of the lateral abdominal muscles, thereby facilitating midline synthesis and avoiding complications related to intra-abdominal hypertension [15].

The aim of this study was to investigate changes in the abdominal wall and the HV/ACV ratio before and after BTA administration in patients undergoing AWR, and its relationship with endotracheal pressure before and after midline closure. Secondary outcomes included wound morbidity, postoperative complications and recurrences.

Methods

This was a two-center, prospective, observational cohort study with a sample comprising 27 consecutive patients who underwent AWR repair between February 2021 and July 2022. The procedure was performed by the same surgical team in both private and academic settings.

Population and data

After approval by the institutions' medical ethics committees (CAAE 43387421.6.0000.5479 and 43,387,421.6.3001.0070), the patients were selected.

The inclusion criteria were: patients with midline complex ventral hernias; primary, incisional or recurrent hernias; a defect size ≥ 10 cm in the transverse diameter; LOD with HV/ACV ≥ 20%; and single or multiple defects provided that they meet at least one the criteria described above. The exclusion criteria were: hernias outside the midline, a defect size < 10 cm or HV/ACV < 20%.

Patients' demographic data were collected during a medical interview. Hernias were classified according to the European Hernia Society (EHS) classification [16] and graded according to a modified Ventral Hernia Working Group [17] scale (m-VHWG).

Treatment algorithm

Patients with a hernia ≥ 10 cm in diameter associated with HV/ACV ≥ 20% were referred for BTA administration. These patients were then re-imaged the day before surgery. The need to perform component separation with open transversus abdominis release (TAR) or open anterior component separation (ACS) can be predicted preoperatively by using a rectus width to defect width ratio (RDR) of < 2:1 (Carbonell equation) [11]. However, following BTA blockade, it may be possible to close the midline by employing the tension-free Rives–Stoppa technique, even if there had previously been a predicted need for component separation, as indicated by the RDR ratio. In this situation, downstaging should be considered, with this being an intraoperative decision. Patients with complex hernias, whose tomographic measurements were < 10 cm for the hernia transverse diameter and with HV/ACV < 20%, underwent surgery without preparation with BTA and were not included in this study.

BTA protocol

Ultrasound-guided BTA was performed between 2 and 6 weeks prior to surgery (target time was 4 weeks). All patients received 150 units of BTA (10 units/mL saline) in three points located on both sides of the abdominal wall, with equal doses in three muscle layers, as described in previously published protocols [18, 19]. OnabotulinumtoxinA was used in all cases, with Prosigne® (Cristália) and Botox® (Allergan) being used in the academic and private settings, respectively. Figure 1 illustrates the technical details pertaining to the BTA injection.

CT measurements

Preoperative CT scans were performed during the diagnostic workup using a 2D cross-sectional, non-contrast protocol. The length and width of the hernia defect and the lateral muscles were identified and measured along their maximum values. The volume of the cavity, the volume of the hernia sac and the HV/ACV ratio were assessed using measurements along three axes according to the method proposed by Tanaka et al. [12] In summary, the limits used for calculating the HV were the parietal peritoneum of the hernia sac in the cranial, caudal, transverse and anterior limits. The posterior limit was determined by the same line as the anterior limit of the abdominal cavity. The ACV was determined anteriorly by the line uniting the muscle groups on either side of the hernia, posteriorly by a line passing through the transverse processes of the vertebrae, cranially by the diaphragm top, caudally by the coccyx and transversely by the parietal peritoneum of each side of the abdominal cavity. The limits were then used for calculating the HV and ACV by using the ellipsoid volume formula: $HV = 4/3.\pi.\left(\frac{a}{2}+\frac{b}{2}+\frac{c}{2}\right)^3$ and $VAC = 4/3.\pi.\left(\frac{A}{2}+\frac{B}{2}+\frac{C}{2}\right)^3$. When multiple associated defects were detected at different positions and with different sizes, the largest one was considered. Figure 2 illustrates the CT measurement details. The peritoneal volume (PV) corresponds to the total visceral volume and was obtained by adding ACV + HV. The peritoneal index (PI) corresponds to the HV/PV ratio and denotes the percentage of the hernia volume over the total visceral volume [20].

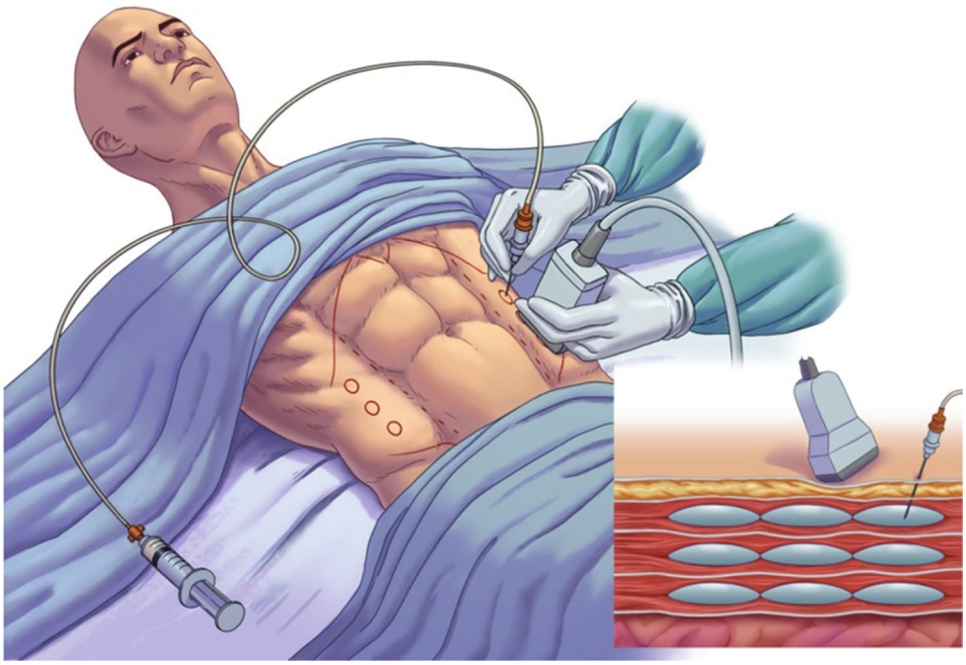

Fig. 1 Patient positioning, anatomical references and technical details for ultrasound-guided BTA injection

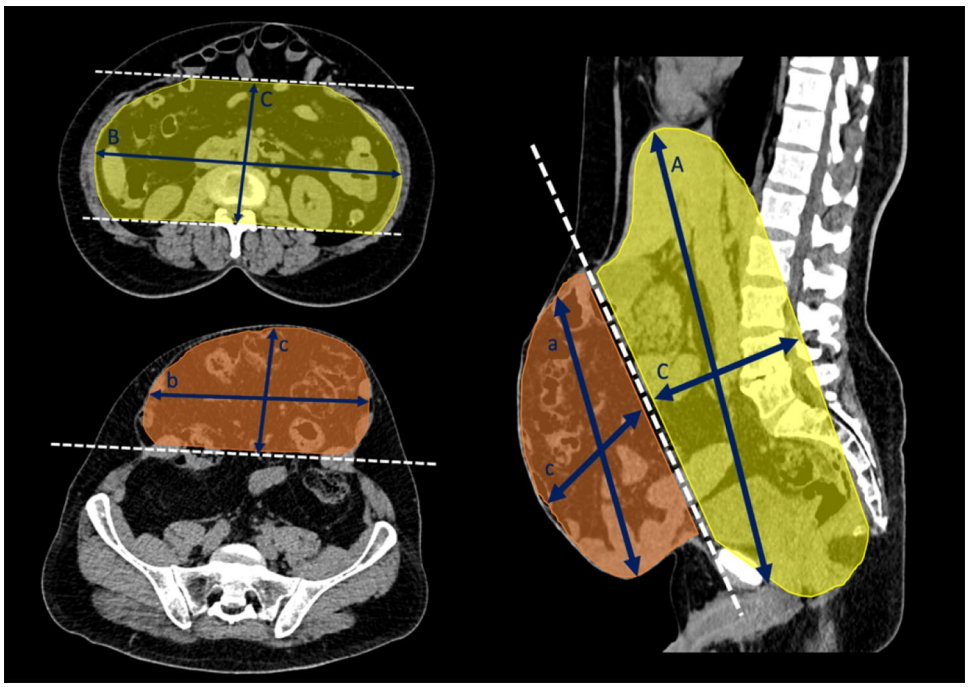

Fig. 2 Measurements of the largest dimensions of HV (orange area; a–b–c axes) and ACV (yellow area; A–B–C axes) in axial and sagittal CT scan images. The percentage of LOD is expressed as HV divided by ACV (LOD = HV/VAC). PV is calculated by sum of HV plus ACV (PV = HV + ACV) and PI is calculated as HV divided by PV (PI = HV/PV)

Initial and preoperative measurements were manually collected from the CT scans by the same surgeon, since there is no software suitable for this purpose. The volumetric calculations were performed using the Tanaka method and calculated with online calculator [21].

Surgical outcomes

Operative details include: midline closure, whether the component separation technique was applied, the type of mesh used and mesh placement, and the need for dermolipectomy or visceral approaches. The criteria for continued intubation and postoperative stay in the surgical intensive care unit (SICU) was presenting an elevation in pulmonary plateau pressure higher than 6 cmH_2O after fascial closure while in

horizontal decubitus [9] (1cmH_2O = 0.735 mmHg was considered, when necessary). The intraoperative measurement of endotracheal pressure was first performed with the fascia still open, and then the postoperative measurement was recorded 20 min after the end of the procedure. Unanticipated intubation during the postoperative period or failure to wean from mechanical ventilation > 48 h was considered respiratory failure.

Wound morbidity was reported as per the following standardized definitions [22]: 90-day surgical site occurrences (SSO), surgical site occurrences requiring procedural interventions (SSOPI) and surgical site infections (SSI). SSIs were classified according to the Centers for Disease Control and Prevention (CDC) guidelines [23] into surface incisional, deep incisional or organ/space infections. We also analyzed unplanned readmissions, recurrences and follow-up.

Statistical analysis

The sample size was calculated using the PSS Health software (https://www.psshealth.com) ($N = 23 + 10\%$ to account for possible losses and refusals) [24]. Descriptive statistics were used for reporting data as counts and percentages. Continuous variables were described as median and interquartile range [Q1–Q3] or mean and standard deviation (mean ± SD). Parametric and non-parametric tests with the appropriate variance assumption were then used as appropriate. A p value < 0.05 was considered statistically significant.

Results

A total of 27 patients were included, of whom 16 (59.3%) were male, with a mean age of 61 years (± 8). The mean body mass index was 26.9 kg/m^2, ranging from 22 kg/m^2 to 32 kg/m^2, 18.5% of whom were obese (BMI > 30 kg/m^2). Eleven patients (40%) had undergone previous surgery due to oncological disease, 2 (7.4%) surgery with a gynecological origin, 3 urological surgery (11.1%) and 6 gastrointestinal surgery (22.2%). Of the patients with a past medical history of malignancy, three had undergone definitive ostomy ($N = 2$ colostomies; $N = 1$ Bricker), and two had previously undergone pelvic radiotherapy.

All hernias were midline hernias; only 1 patient had a primary hernia (3.7%), whereas the 26 other patients presented with incisional hernias (96.3%), 3 (11.1%) being recurrent incisional hernias, but none of them had previously undergone component separation.

The mean time between BTA administration and the surgical procedure was 31 days (range 22–51). Table 1 shows the demographic details, preoperative information and hernia characteristics.

Table 1 Patients' demographic details, preoperative information and hernia characteristics

Characteristics	*n* (%)
Santa Casa	18 (66.7)
Hospital Alemão Oswaldo Cruz	9 (33.3)
Age, years, mean ± SD (range)	61 ± 8 [43–72]
Male gender	16 (59.3)
BMI, mean ± SD (range)	26.9 ± 5 (22–32)
Obesity (BMI > 30)	5 (18.5)
Hypertension	4 (14.8)
Diabetes	6 (22.2)
Smoking status	
Current	1 (3.7)
Former	6 (22.2)
Never	20 (74.1)
Ostomy	3 (11.1)
Colostomy	2 (7.4)
Bricker	1 (3.7)
Oncological disease	11 (40.7)
Gastrointestinal	6 (22.2)
Urological	3 (11.1)
Gynecological	2 (7.4)
Previous radiotherapy	2 (7.4)
Hernia type	
Incisional	26 (96.3)
Primary	1 (3.7)
Recurrent incisional hernia	3 (11.1)
Hx component separation	0
Modified VHWG	
Grade 1	6 (22.2)
Grade 2	16 (59.3)
Grade 3	5 (18.5)
Grade 4	0
EHS classification	
M2M3-W3	3 (11.1)
M3M4-W3	1 (3.7)
M1M2M3-W3	2 (7.4)
M2M3M4-W3	15 (55.6)
M2M3M4M5-W3	6 (22.2)
BTA injection (days before surgery), mean (min–max)	31 (22–51)

When comparing the tomographic measurements before and after BTA, there was a reduction in the mean transverse diameter of the hernia of 1.92 cm (15.09 ± 3.14 cm before and 13.17 ± 2.92 cm after, $p = 0.002$). With respect to the lateral abdominal musculature, a reduction in thickness (2.49 ± 0.64 before, and 1.61 ± 0.50 after, $p < 0.001$) and elongation (13.28 ± 2.70 before, and 16.40 ± 2.64 after, $p < 0.001$) was observed. The mean RDR ratio showed an

increase from 1.05 ± 0.45 to 1.17 ± 0.49 before and after ($p < 0.001$), respectively.

The mean HV decreased from 2.94 ± 0.93L to 2.41 ± 0.77L ($p < 0.001$), and the mean VAC increased from 9.71 ± 2.53 L to 10.33 ± 2.42 L ($p = 0.003$). PV did not show any volumetric variation (12.65 ± 3.22L before and 12.74 ± 3.06L after) with $p = 0.284$. PI decreased from 23.26 ± 4.7% to 18.9 ± 4.9% ($p < 0.001$), and the HV/ACV ratio decreased from 30.25 ± 5.01% to 23.45 ± 6.14% ($p < 0.001$). Table 2 shows the details relative to changes in abdominal wall, hernia and volumetry measurements post-BTA administration.

In intraoperative data, midline fascial closure was possible in 92.6% of cases ($N = 25$), while in 77.8%, component separation was necessary ($N = 21$). Polypropylene heavyweight mesh was preferably (92.6%) used, and the retromuscular position was the chosen placement in most cases (88.9%). However, there were two cases in which it was not possible to close the midline; therefore, a composite mesh was used for bridging when it was not possible to close the posterior sheath completely. The mean variation of the endotracheal plateau pressure was 3.53 cmH_2O (the mean intraoperative and postoperative values were 20.29 ± 3.01 and 23.82 ± 2.88, respectively), with 92.6% of patients extubated in the operating room. Of the total patients, two were extubated in SICU due to plateau variation > 6 cmH_2O and presented no signs indicative of respiratory failure (Table 3).

At the 90-day follow-up, 25.9% ($N = 7$) of the patients presented with wound morbidity, most of them SSO, and one of them requiring an interventional drainage procedure and vacuum therapy. Unplanned readmission occurred in three cases, and all of them underwent reoperation. The median length of stay was 3.8 days [IQR 3–4] ,but it increased to 10.3 days [IQR 7.75–13] in the cases of readmission. After a median 15.9 months [IQR 10.70–19.06], two patients experienced recurrences (7.4%). The two recurrences occurred in patients who needed unplanned readmission and reoperation. Table 4 shows the details regarding postoperative outcomes.

Table 3 Intraoperative information

Intraoperative information	*n* (%)
Rives–Stoppa	6 (22.2)
Component separation technique	21 (77.8)
ACS	2 (7.4)
TAR	19 (70.3)
Primary fascial closure	25 (92.6)
Mesh type	
Polypropylene heavyweight mesh	25 (92.6)
Composite mesh	2 (7.4)
Mesh position	
Retromuscular	24 (88.9)
Onlay	1 (3.7)
Bridging	2 (7.4)
Previous mesh removal	2 (7.4)
Dermolipectomy	4 (14.8)
Intestinal resection	1 (3.7)
Enterorrhaphy	2 (7.4)
Plateau pressure cmH_2O, mean ± SD (range)	
Intraoperative	20.29 ± 3.01 (16–27)
Postoperative	23.82 ± 2.88 (20–31)
Δ Plateau	3.53 ± 1.70 (1–8)

Discussion

Preoperative preparation of patients with complex ventral hernias helps to optimize fascial closure rates and postoperative results. Recently, the administration of BTA to the lateral abdominal wall has emerged as a technique capable of promoting elongation of the muscle fibers in this area and reducing the volume of the hernia, which is strategically relevant in cases of large defects associated with LOD. The results from the cohort of 27 patients treated in this study according to a standardized algorithm showed that BTA can be an important tool in the preparation of complex cases, attaining a primary fascial closure rate of 92.6%. In this series, the wound morbidity rate was 25.9%, with a

Table 2 Computed tomography measurements and volumetry

Mean ± SD (min—max)	Before BTA	After BTA	*p*-value
Hernia width, cm	15.09 ± 3.14 (12–23)	13.17 ± 2.92 (9–19)	0.002
Lateral muscle width, cm	2.49 ± 0.64 (1.9–3.8)	1.61 ± 0.50 (1.3–2.5)	< 0.001
Lateral muscle length, cm	13.28 ± 2.70 (10–18)	16.40 ± 2.64 (12–20.5)	< 0.001
RDR ratio	1.05 ± 0.45 (0.50–1.91)	1.17 ± 0.49 (0.58–2.2)	< 0.001
HV, L	2.94 ± 0.93 (1.8–4.51)	2.41 ± 0.77 (1.5–3.6)	< 0.001
ACV, L	9.71 ± 2.53 (4.40–12.9)	10.33 ± 2.42 (4.91–13.5)	0.003
PV (ACV + HV), L	12.65 ± 3.22 (5.51–18.51)	12.74 ± 3.06 (5.31–16.72)	0.284
PI (HV/PV), %	23.26 ± 4.7 (14.1–31.5)	18.90 ± 4.9 (9.1–26.1)	< 0.001
HV/ACV (Tanaka score), %	30.25 ± 5.01 (22.2–41.42)	23.45 ± 6.14 (13.8–35.4)	< 0.001

Table 4 Surgical outcomes

Outcome	*n* (%)
Extubation in surgical center	25 (92.6)
Postoperative stay in SICU (plateau ≥ 6 cmH_2O)	2 (7.4)
Postoperative respiratory failure	0
Wound morbidity (90 days)	7 (25.9)
SSO	4 (14.8)
Seroma	3 (11.1)
Hematoma	1 (3.7)
SSI	2 (7.4)
Superficial	1 (3.7)
Deep	1 (3.7)
SSOPI	1
Median length of hospital stay, [IQR]	3.8 [3–4]
Unplanned readmission	3 (11.1)
Median length of hospital stay upon readmission, [IQR]	10.3 [7.75–13]
Reoperation	3 (11.1)
Recurrence	2 (7.4)
Follow-up, months, median [IQR]	15.9 [10.70–19.06]

recurrence rate of 7.4%, which can be considered low in a challenging and technically demanding group. Furthermore, there were no cases of intra-abdominal hypertension. Our hypothesis is that these favorable results are related to abdominal compliance resulting from muscle fiber blockade after BTA injection, as herein studied by measuring the hernia defect, muscle thickness and length of lateral fibers, and by assessing volumetric behavior with respect to HV, ACV and their ratios (ACV + HV, HV/PV, HV/VAC) using CT scans from before and after the BTA application.

With regard to tomographic measurements, we detected a slight reduction in the mean transverse diameter of the hernia of 1.92 cm, elongation in the mean lateral musculature of 3.12 cm on each side and a decrease in the mean lateral muscle thickness of 0.88 cm. Other authors found a 0.9–5 cm myofascial advancement and 0.5–1 cm decrease in thickness with BTA. [15, 19, 25–28]. When considering the 6 cm elongation of the fibers in the lateral muscles (3.12 cm on each side), it may result in up to an 8 cm circumferential gain in the abdominal continent if we include an additional 2 cm due to the reduction in the diameter of the hernia. If we consider these values, the circumferential increase could facilitate closure in less complex cases; however, it is not enough to approximate the rectus abdominis muscles in large defects, such as those included in this study, since the mean transverse diameter observed was 15 cm before and 13 cm after BTA administration. Therefore, in 77.8% of cases, it was necessary to perform component separation. Although the RDR ratio predicted the necessity of component separation in all cases, the use of BTA promoted downstaging in six cases.

The relationship between the length of the lateral muscles and abdominal content becomes more evident when we consider the volume of the abdominal viscera. The PV measurements did not change significantly and tended to remain constant. This can be explained by the fact that although the elongation of the lateral fibers can increase ACV, there appears to be a compensatory reduction in HV, resulting in a similar calculation of PV. This means that when the circumference of the abdomen increases, the viscera may occupy more of the abdominal cavity and less of the hernia sac. For this reason, we noticed a reduction in the HV/ACV ratio. Fafaj et al. [29] reported that an HV/ACV < 25% is a sensitive predictor of midline closure in large hernias. Hence, the reduction in the HV/ACV ratio after BTA may have contributed to our midline closure rate of 92.6%. Yurtkap et al. [30] identified less variation when comparing HV/ACV in patients preoperatively prepared with BTA and/or PPP and midline closure was possible in 82% of the cases. Therefore, midline closure seems to be more associated with abdominal cavity compliance due to the greater elasticity of the muscle fibers elicited by the BTA blockade, rather than solely due to the value found for lateral fiber advancement. Sabbagh et al. [20] demonstrated that a PI < 20% was associated with tension-free midline closure and Oprea et al. [31] reported increased postoperative intra-abdominal and plateau pressures with a PI > 33%. In our series, the PI value was reduced from 23.26 to 18.90%. Midline closure and total restitution of the PV into the cavity may result in changes in abdominal physiology. In more severe cases, the increase in intra-abdominal pressure can lead to impaired respiratory dynamics and hemodynamic instability. Said et al. [13] observed respiratory failure or extubation failure in 29%

of cases, with a median HV/ACV ratio of 30.6% being an important predictor of the need for postoperative care in the SICU. In our series, we found a reduction in the HV/ACV ratio from 30.25% to 23.45% due to the action of the neuromuscular blockade achieved with BTA, which may have contributed to the fact that we did not observe respiratory failure or intra-abdominal hypertension. Two patients (7.6%) stayed in the SICU postoperatively for safety reasons due to a plateau variation > 6 cm, according to the predictive results of Blatnik et al. [9] and they did not experience extubation failure with the use of dexmedetomidine. Deeremberg et al. [32] reported a 7% postoperative respiratory failure rate requiring re-intubation.

Regarding postoperative results, we observed a 25.9% rate ($N = 7$) of wound morbidity, of which six cases were treated clinically. Three patients (11%) required reoperation. A vacuum dressing was applied to treat seroma with skin and subcutaneous dehiscence in one patient. Two laparotomies were performed: one patient with a permanent colostomy and a bridge mesh had a deep infection and underwent mesh removal. This was considered a recurrence as the midline remained open. We believe that both the presence of the colostomy, its permanent colonization and the presence of the bridging mesh may have contributed to the deep infection. Bridging repair associated with infection is related to higher recurrence rates [33–35]. The other patient presented late intestinal subocclusion, probably because of the presence of multiple ileal adhesions due to previous radiotherapy. The condition did not resolve after clinical treatment, requiring median laparotomy with mesh opening and right hemicolectomy. The mesh was not removed in the emergency surgery. A minor recurrence was diagnosed in the inferior midline 2 months later. Both reoperated patients chose not to have further surgery for AWR. Other series of AWR with LOD have reported reoperation rates of 8–15% [36–38].

Our study has several limitations that deserve consideration. First, the relatively small sample size may be insufficient for valid comparisons. Second, the tomographic measurements were performed by a surgeon (who is one of the co-authors of this study) with experience of these modalities, rather than by a radiologist, as there is no support for radiological interventions or specific tomographic reports following routine abdominal wall surgery. Third, there was no blinding, which means there was a possibility of bias. Finally, the surgeons who performed the surgeries have extensive experience in AWR and component separation and, for this reason, the satisfactory primary fascial closure results might not be reproducible by other surgeons with less experience.

Conclusion

In this series of 27 patients undergoing AWR previously prepared with BTA, a reduction in HV and HV/ACV was observed. Although there was slight postoperative endotracheal elevation, no extubation failure was encountered. This was a study with a small number of cases and with some possible biases, mainly related to the tomographic measurements. Therefore, randomized controlled trials with a larger number of patients should be undertaken to verify these results and enable meaningful conclusions to be drawn regarding the role of BTA in the surgical armamentarium for complex hernia repair.

Funding Supported by Fundação Arnaldo Vieira de Carvalho. The BTA was donated by Cristália (Prosigne®) and used in all cases studied in academic settings. BTA is not available for use in the Brazilian public health system.

Declarations

Conflict of interest SR has received personal fees for consulting from Medtronic, Richard Wolf and B. Braun; they are not related to this study. The other authors declare no conflict of interest.

Ethical approval The study protocol was approved by the ethics committees of the institutions (CAAE 43387421.6.0000.5479 and 43387421.6.3001.0070).

Human and animal rights This research did not involve the use of animals.

Informed consent Informed consent was obtained from all individual participants included in the study.

References

1. Plymale MA, Ragulojan R, Davenport DL, Roth JS (2017) Ventral and incisional hernia: the cost of comorbidities and complications. Surg Endosc 31(1):341–351. https://doi.org/10.1007/s00464-016-4977-8
2. Berger RL, Li LT, Hicks SC, Davila JA, Kao LS, Liang MK (2013) Development and validation of a risk-stratification score for surgical site occurrence and surgical site infection after open ventral hernia repair. J Am Coll Surg 217(6):974–982. https://doi.org/10.1016/j.jamcollsurg.2013.08.003
3. Schlosser KA, Renshaw SM, Tamer RM, Strassels SA, Poulose BK (2023) Ventral hernia repair: an increasing burden affecting abdominal core health. Hernia 27(2):415–421. https://doi.org/10.1007/s10029-022-02707-6
4. Poulose BK, Harris DA, Phillips S, Janczyk RJ, Yunis J, Voeller GR, Carbonell A, Warren J, Stoikes N, Webb D, Hope WW, Rosen MJ, Americas Hernia Society Quality Collaborative (2018) Reducing early readmissions after ventral hernia repair with the americas hernia society quality collaborative. J Am Coll Surg 226(5):814–824. https://doi.org/10.1016/j.jamcollsurg.2018.01.048

5. Howard R, Thompson M, Fan Z, Englesbe M, Dimick JB, Telem DA (2019) Costs associated with modifiable risk factors in ventral and incisional hernia repair. JAMA 2(11):e1916330. https://doi.org/10.1001/jamanetworkopen.2019.16330
6. Deerenberg EB, Timmermans L, Hogerzeil DP, Slieker JC, Eilers PH, Jeekel J, Lange JF (2015) A systematic review of the surgical treatment of large incisional hernia. Hernia 19(1):89–101. https://doi.org/10.1007/s10029014-1321-x
7. Sabbagh C, Dumont F, Fuks D, Yzet T, Verhaeghe P, Regimbeau JM (2012) Progressive preoperative pneumoperitoneum preparation (the Goni Moreno protocol) prior to large incisional hernia surgery: volumetric, respiratory and clinical impacts. A prospective study. Hernia 16(1):33–40. https://doi.org/10.1007/s10029-011-0849-2
8. Weissler JM, Lanni MA, Tecce MG, Carney MJ, Shubinets V, Fischer JP (2017) Chemical component separation: a systematic review and meta-analysis of botulinum toxin for management of ventral hernia. J Plast Surg HandSurg 51(5):366–374. https://doi.org/10.1080/2000656X.2017.1285783
9. Blatnik JA, Krpata DM, Pesa NL, Will P, Harth KC, Novitsky YW, Rowbottom JR, Rosen MJ (2012) Predicting severe postoperative respiratory complications following abdominal wall reconstruction. Plast Reconstr Surg 130(4):836–841. https://doi.org/10.1097/PRS.0b013e318262f160
10 Zolin SJ, Fafaj A, Krpata DM (2020) Transversus abdominis release (TAR): what are the real indications and where is the limit? Hernia 24(2):333–340. https://doi.org/10.1007/s10029-020-02150-5
11. Love MW, Warren JA, Davis S, Ewing JA, Am H, Cobb WS, Carbonell AM (2021) Computed tomography imaging in ventral hernia repair: can we predict the need for myofascial release? Hernia 25(2):471–477. https://doi.org/10.1007/s10029-020-02181-y
12 Tanaka EY, Yoo JH, Rodrigues AJ, Utiyama EM, Birolini D, Rasslan S (2010) A computerized tomography scan method for calculating the hernia sac and abdominal cavity volume in complex large incisional hernia with loss of domain. Hernia 14:63–69
13. Said S, Thomas J, Montelione K, Fafaj A, Beffa L, Krpata D, Prabhu A, Rosen M, Petro C (2022) Tanaka score predicts surgical intensive care admission following abdominal wall reconstruction. Hernia 26(3):873–880. https://doi.org/10.1007/s10029-022-02605-x
14. Alam NN, Narang SK, Pathak S, Daniels IR, Smart NJ (2016) Methods of abdominal wall expansion for repair of incisional hernia: a systematic review. Hernia 20:191–199. https://doi.org/10.1007/s10029-016-1463-0
15. Ibarra-Hurtado TR, Nuño-Guzmán CM, Miranda-Díaz AG, Troyo-Sanromán R, Navarro-Ibarra R, Bravo-Cuéllar L (2014) Effect of botulinum toxin type A in lateral abdominal wall muscles thickness and length of patients with midline incisional hernia secondary to open abdomen management. Hernia 18:647–652. https://doi.org/10.1007/s10029-014-1280-2
16. Muysoms FE, Miserez M, Berrevoet F, Campanelli G, Champault GG, Chelala E, Dietz UA, Eker HH, El Nakadi I, Hauters P, Hidalgo Pascual M, Hoeferlin A, Klinge U, Montgomery A, Simmermacher RK, Simons MP, Smietański M, Sommeling C, Tollens T, Vierendeels T, Kingsnorth A (2009) Classification of primary and incisional abdominal wall hernias. Hernia 13:407–414. https://doi.org/10.1007/s10029-009-0518-x
17. Kanters AE, Krpata DM, Blatnik JA, Novitsky YM, Rosen MJ (2012) Modified hernia grading scale to stratify surgical site occurrence after open ventral hernia repairs. JAmCollSurg 215:787–793. https://doi.org/10.1016/j.jamcollsurg.2012.08.012
18. Deerenberg EB, Elhage SA, Raible RJ, Shao JM, Augenstein VA, Heniford BT, Lopez R (2021) Image-guided botulinum toxin injection in the lateral abdominal wall prior to abdominal wall reconstruction surgery: review of techniques and results. Skeletal Radiol 50:1–7. https://doi.org/10.1007/s00256-020-03533-6
19. Elstner KE, Read JW, Rodriguez-Acevedo O, Cosman PH, Dardano AN, Jacombs ASW et al (2017) Preoperative chemical component relaxation using Botulinum toxin A: enabling laparoscopic repair of complex ventral hernia. Surg Endosc 31:761–768. https://doi.org/10.1007/s00464-016-5030-7
20. Sabbagh C, Dumont F, Robert B, Badaoui R, Verhaeghe P, Regimbeau JM (2011) Peritoneal volume is predictive of tension-free fascia closure of large incisional hernias with loss of domain: a prospective study. Hernia 15(5):559–565. https://doi.org/10.1007/s10029-011-0832-y
21. Herniacalc. Tool for complex hernia surgery. https://haru.med.br/herniacalc/ Accessed between February 2021 and July 2022.
22. Haskins IN, Horne CM, Krpata DM, Prabhu AS, Tastaldi L, Perez AJ (2018) A call for standardization of wound events reporting following ventral hernia repair. Hernia 22(5):729–736. https://doi.org/10.1007/s10029-018-1748-6
23. Surgical site infection (SSI) (2018) Event (Centers for disease control and prevention)
24. Borges RB, Mancuso ACB, Camey SA, Leotti VB, Hirakata VN, Azambuja GS, et al (2020) Power and Sample Size for Health Researchers: a tool for calculating sample size and statistical power designed for health researchers. Clin Biomed Res 40:247–253. https://doi.org/10.22491/2357-9730.109542.
25. Timmer AS, Claessen JJM, Atema JJ, Rutten MVH, Hompes R, Boermeester MA (2021) A systematic review and meta-analysis of technical aspects and clinical outcomes of botulinum toxin prior to abdominal wall reconstruction. Hernia 25(6):1413–1425. https://doi.org/10.1007/s10029-021-02499-1
26. Rodriguez-Acevedo O, Elstner KE, Jacombs ASW, Read JW, Martins RT, Arduini F, Wehrhahm M, Craft C, Cosman PH, Dardano AN, Ibrahim N (2018) Preoperative Botulinum toxin A enabling defect closure and laparoscopic repair of complex ventral hernia. Surg Endosc 32(2):831–839. https://doi.org/10.1007/s00464-017-5750-3
27. Farooque F, Jacombs AS, Roussos E, Read JW, Dardano AN, Edye M, Ibrahim N (2016) Preoperative abdominal muscle elongation with botulinum toxin A for complex incisional ventral hernia repair. ANZ J Surg 86(1–2):79–83. https://doi.org/10.1111/ans.13258
28. Claessen JJM, Timmer AS, Hemke R, Atema JJ, Hompes R, Boermeester MA, Rutten MVH (2023) A computed tomography study investigating the effects of botulinum toxin injections prior to complex abdominal wall reconstruction. Hernia 27(2):281–291. https://doi.org/10.1007/s10029-022-02692-w
29. Fafaj A, Thomas J, Zolin SJ, Poli de Figueiredo SM, Tastaldi L, Liu PS, Petro CC, Krpata DM, Prabhu AS, Rosen MJ (2021) Can Hernia Sac to Abdominal Cavity Volume Ratio Predict Fascial Closure Rate for Large Ventral Hernia? Reliability of the Tanaka Score. J Am Coll Surg 232(6):948–953. https://doi.org/10.1016/j.jamcollsurg.2021.03.009
30. Yurtkap Y, van Rooijen MMJ, Roels S, Bosmans JML et al (2021) Implementing preoperative Botulinum toxin A and progressive pneumoperitoneum through the use of an algorithm in giant ventral hernia repair. Hernia 25(2):389–398. https://doi.org/10.1007/s10029-020-02226-2
31. Oprea V, Mardale S, Buia F, Gheorghescu D, Nica R, Zdroba S, Grad O (2021) The influence of transversus abdominis muscle release (TAR) for complex incisional hernia repair on the intraabdominal pressure and pulmonary function. Hernia 25(6):1601–1609. https://doi.org/10.1007/s10029-021-02395-8
32. Deerenberg EB, Elhage SA, Shao JM, Lopez R, Raible RJ, Kercher KW, Colavita PD, Augenstein VA, Heniford BT (2020) The effects of preoperative botulinum toxin a injection on

abdominal wall reconstruction. J Surg Res 260:251–258. https://doi.org/10.1016/j.jss.2020.10.028
33. Holihan JL, Askenasy EP, Greenberg JA, Keith JN, Martindale RG, Roth JS, Mo J, Ko TC, Kao LS, Ventral Hernia Outcome Collaboration Writing Group (2016) Component separation vs. bridged repair for large ventral hernias: a multi-institutional risk-adjusted comparison, systematic review, and meta-analysis. Surg Infect (Larchmt). 17(1):17–26. https://doi.org/10.1089/sur.2015.124
34. Awad ZT, Puri V, LeBlanc K, Stoppa R, Fitzgibbons RJ Jr, Iqbal A, Filipi CJ (2005) Mechanisms of ventral hernia recurrence after mesh repair and a new proposed classification. J Am Coll Surg 201(1):132–140. https://doi.org/10.1016/j.jamcollsurg.2005.02.035
35. Deerenberg EB, Shao JM, Elhage SA, Lopez R, Ayuso SA, Augenstein VA et al (2021) Preoperative botulinum toxin A injection in complex abdominal wall reconstruction- a propensity-scored matched study. Am J Surg 222(3):638–642. https://doi.org/10.1016/j.amjsurg.2021.01.010
36. Bueno-Lledó J, Carreño-Saenz O, Torregrosa-Gallud A, Pous-Serrano S (2020) Preoperative botulinum toxin and progres- sive pneumoperitoneum in loss of domain hernias-our first 100 cases. Front Surg 7:3. https://doi.org/10.3389/fsurg.2020.00003
37. Bueno-Lledó J, Torregrosa A, Jiménez R, Pastor PG (2018) Preoperative combination of progressive pneumoperitoneum and botulinum toxin type A in patients with loss of domain hernia. Surg Endosc 32(8):3599–3608. https://doi.org/10.1007/s00464-018-6089-0
38. Kingsnorth AN, Sivarajasingham N, Wong S, Butler M (2004) Open mesh repair of incisional hernias with significant loss of domain. Ann R Coll Surg Engl 86(5):363–366. https://doi.org/10.1308/147870804236

Publisher's Note Springer Nature remains neutral with regard to jurisdictional claims in published maps and institutional affiliations.

Springer Nature or its licensor (e.g. a society or other partner) holds exclusive rights to this article under a publishing agreement with the author(s) or other rightsholder(s); author self-archiving of the accepted manuscript version of this article is solely governed by the terms of such publishing agreement and applicable law.